


# CELL SHAPES: \*



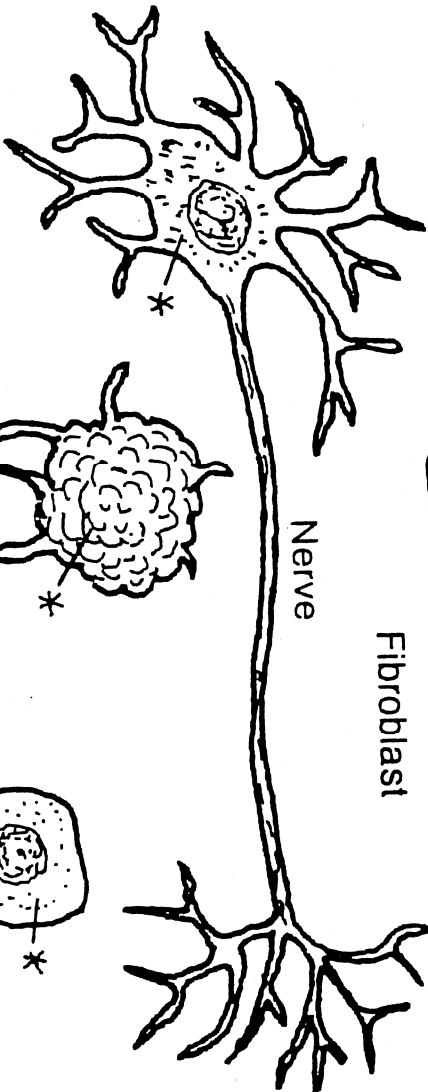
Smooth muscle




Fibroblast



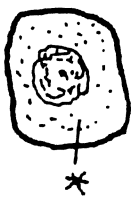
Skeletal muscle



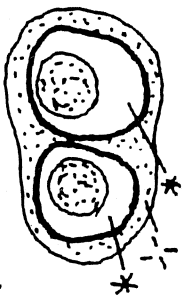
Nerve



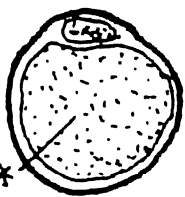
White blood



Epithelial



2 cartilage cells



Fat